

Evaluating the Measuring Software Package Metron-PX for Morphometric Description of Equine Hoof Radiographs

Jairo Vargas Rocha, DVM,^a Christophorus J. Lischer, DVM Habil, ECVS,^a Martin Kummer, DVM,^a Michael Hässig, DVM Habil, MPH, FVH, ECBHM,^b Jörg Andreas Auer, DVM Prof, ACVS, ECVS^a

ABSTRACT

Reasons for Performing the Study: Radiography is still the most common diagnostic tool to assess hoof injury in horses. Radiologic measurements are important in the evaluation of the quality of hoof trimming or displacement of the pedal bone in laminitic hooves. A specific program called Metron-PX was designed to measure distances and angles in the hoof. The purpose of this study was to determine the exactness of the radiologic measurements obtained with this program.

Design: In vitro, experimental study.

Procedure: Evaluation of the software Metron-PX was based on 88 radiographs taken of 2 forelimbs of 2 orthopedically sound horses that were humanely euthanized for reasons unrelated to this study. In a total of 33 parameters obtained from the dorsopalmar and lateromedial radiographs, the effect caused by repeated measurements of the same digitalized radiograph in 2 magnifications, the radiographic technique, and different operators was evaluated. On the lateromedial radiograph, these measurements were compared with the corresponding sagittal section of the anatomic specimens (anatomic standard).

Results: Statistically significant differences were seen among the measurements obtained of the 33 parameters in the 4 different tests. These differences correspond to

the low values of the variation coefficient of the measurements taken in each test and the difficulty of cutting the foot precisely in the sagittal plane that coincides with the radiographic projection.

Conclusions and Clinical Relevance: Even though there are differences among the measurements in the 4 tests, most of them are not considered clinically relevant. The radiographic technique and the Metron-PX software can be used to objectively measure most of the parameters predefined by the software.

INTRODUCTION

There may be no other routine procedure performed on the equine athlete that has more influence on soundness than hoof preparation and shoeing. An important aspect of hoof trimming is the concept of hoof balance, which can be divided into geometric, dynamic, and natural balance.¹ A complete description of the balanced hoof of a solitary limb addresses toe length, hoof angle, mediolateral hoof orientation, insensitive sole, frog and bar thickness, wall contour, and ground surface.² The essential nature of hoof balance in sport horses is increasingly taken into account in the prevention and the treatment of lameness in the equine distal limb. Despite many theories, the way to obtain appropriate trimming for a given conformation remains controversial.

Objective assessment of geometric hoof balance with the use of hoof measurements and quantitative description of the position of the digital bones in relation to the hoof capsule have been proposed to achieve ideal trimming for an individual horse's conformation. The position and alignment of the bones to one another and to the hoof capsule and changes in these measurements after trimming or shoeing can be assessed through radiographs using radio-opaque markers. However, proper patient positioning and high-quality, repeatable radiographic technique is mandatory if reliable diagnos-

From the Equine Hospital^a and Department for Food Animals, Section of Herd Health,^b Vetsuisse Faculty, University of Zurich, Switzerland. Reprint requests: Christoph J. Lischer, Equine Hospital, Vet-Suisse Faculty University of Zürich, Winterthurerstrasse 260, CH-8057 Zürich, Switzerland.
0737-0806/\$ - see front matter
© 2004 Elsevier Inc. All rights reserved.
doi:10.1016/j.jevs.2004.07.002



Figure 1. All radiographs were taken with the limbs positioned on a special platform, which allows taking dorsopalmar radiographs at the same level as the lateromedial.

tic radiographs are to be produced. Preparation of the foot, positioning of the hoof, and radiographic techniques have been described by other authors,³⁻⁸ and the normal radiographic anatomy of the digit is illustrated elsewhere.^{3,9-11}

The Metron-PX software package was developed to measure photographs and radiographs of the horse's hoof. The manufacturers claim that the software is able to make precise measurements of predefined values for the various geometric aspects of the hoof and the bone from digitized radiographic images. Using the software, a total of 19 parameters are computed from the lateromedial radiograph and 14 parameters from the horizontal dorsopalmar radiograph. The parameters are divided into bone parameters (digital bones), hoof parameters (horn capsule), and stance parameters (joint angles).

Assuming these measurements are reliable, it should be possible to keep track of conformational changes in the lower leg and the hoof. In this way, a precise hoof health record can be maintained and any changes that occur can be easily and quickly recognized.¹²

The aim of this study was to determine the exactness of the various parameters of the equine hoof obtained with the Metron-PX software.

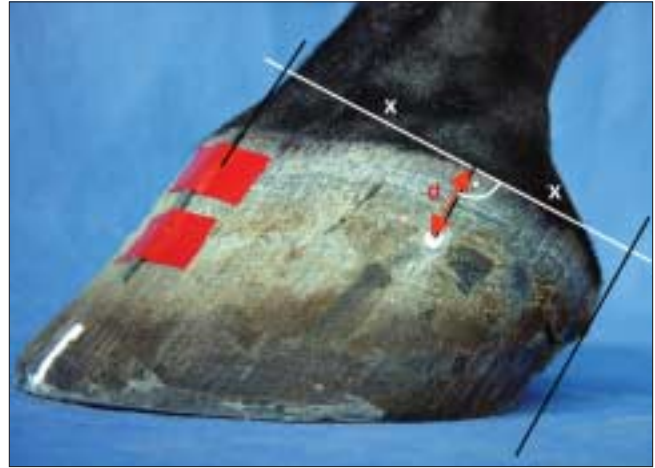

Figure 2. Main beam of the X-Ray generator is positioned 2 cm (d) below the coronary band and at a right angle to the middle of the line between the bulbs of the heel and the dorsal aspect of the hoof wall.

MATERIALS AND METHODS

Equine Limbs

For this study, 2 left forelimbs of 2 orthopedically sound horses that were humanely euthanized, for reasons unrelated to this study, were selected. The distal limbs were obtained by cutting through the carpometacarpal joint. After the shoe was removed, the sole and the wall were cleaned using a hoof pick and wire brush. The distal limb was frozen at -20°C in an anatomic weight-bearing position of the fetlock. Each forelimb underwent only a single freeze/thaw cycle.

Radiographs

All feet were radiographed with the limb in a vertical position. Dorsal and medial hoof wall, the bulbs, and the frog were marked with flexible bands of lead and barium paste, respectively, as described by Kummer et al.¹³ The current study required the positioning of the limbs on a special platform, which decreases the errors generated by incorrect positioning of the hoof in relation to the radiograph generator (Fig 1). The radiograph generator is attached to a movable arm, which is connected to the platform to keep the central radiographic beam in a defined distance above and parallel to the ground when rotating it from the dorsopalmar to the lateromedial view.¹³

In the operating manual of Metron-PX, the exact localization of the central beam of the radiograph is not de-

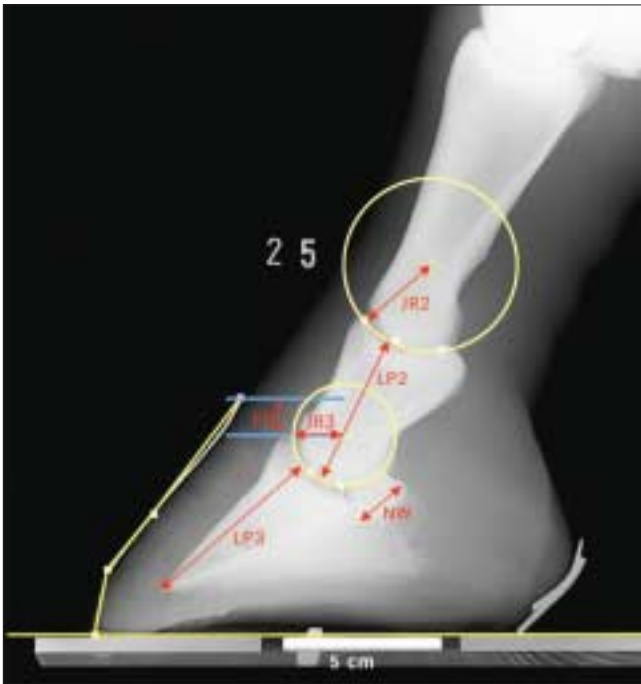

Figure 3. Bone parameters of the laterolateral radiograph. JR2: P1-P2 joint radius, distance from the centre of rotation to the articular surface. JR3: P2-P3 joint radius, distance from the centre of rotation to the articular surface. LP2: Length of P2, the distance between the two rotation centres of the distal interphalangeal joints minus P1-P2 joint radius (JR2) and plus P2-P3 joint radius (JR3). LP3: Length of P3, from the tip of P3 to the centre of rotation of the distal interphalangeal joint minus P2-P3 joint radius (JR3) NW: Navicular bone width, the width of the navicular bone (maximum width as seen on this view). FD: Founder Distance is the P3 descent. Distance between two horizontal lines through the hairline and the top of extensor process of P3, respectively. It is a measure of the height of P3 in the hoof capsule.

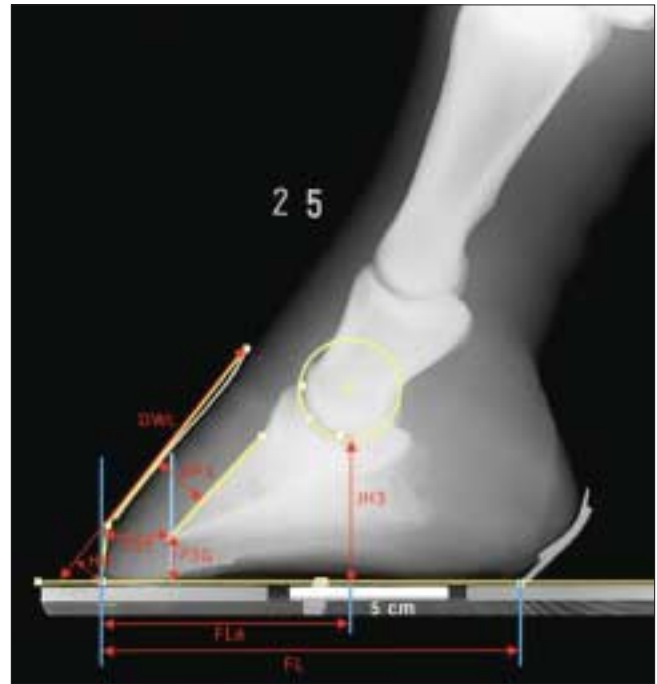


Figure 4. Hoof capsule parameters (distances) of the laterolateral radiograph. P3G: Tip of P3 to the ground, vertical distance from the tip of P3 to the horizontal line of the ground. P3T: P3 to toe, from the tip of P3 to the dorsal hoof wall, measured horizontally. JH3: P2-P3 joint height, from the coffin joint's center of rotation to the ground plane, minus the radius of the joint (JR3). FL: Foot width, the length of the hard hoof support at ground. FLA: Is not a parameter. The distance is used to calculate the percentage of Toe/Heel ratio (see Flat % in Fig 1). HD: Hoof Deviation, sum of the distances between the four points and the "hoof gauge line." HP3: Hoof-P3 distance, minimum distance between the dorsal mid-line of P3 and the exterior hoof wall. DWL: Dorsal wall length, from the hair line to the contact point with ground of the dorsal hoof wall.

fined. In accordance with the radiographic technique described by Redden⁸ and Kummer et al,¹³ the following locations were determined: The lateromedial radiographs were taken with the central beam of the radiographic generator positioned 2 cm below the coronary band and at a right angle to the middle of the line between the bulbs of the heel and the dorsal aspect of the hoof wall (Fig 2). The radiographic beam was aligned parallel to the ground and to the long axis of the distal sesamoid bone. The dorsopalmar radiographs were taken at the same level using the platform designed especially for this study. The ra-

diographic beam was positioned at the median of the hoof capsule, parallel to the ground and at a right angle relative to the lateromedial radiographic plane.

The radiographic generator used was a Gierrth HF 200. The focus film distance for each projection was 90 cm, and 20.3 cm × 25.4 cm cassettes containing a rare earth-imaging system were used. Exposure factors were 5 mA per second at 58 Kv for the lateromedial projection and 5 mA per second at 62 Kv for the dorsopalmar projection. The radiographs were digitalized with a scanner and imported into Metron-PX program.

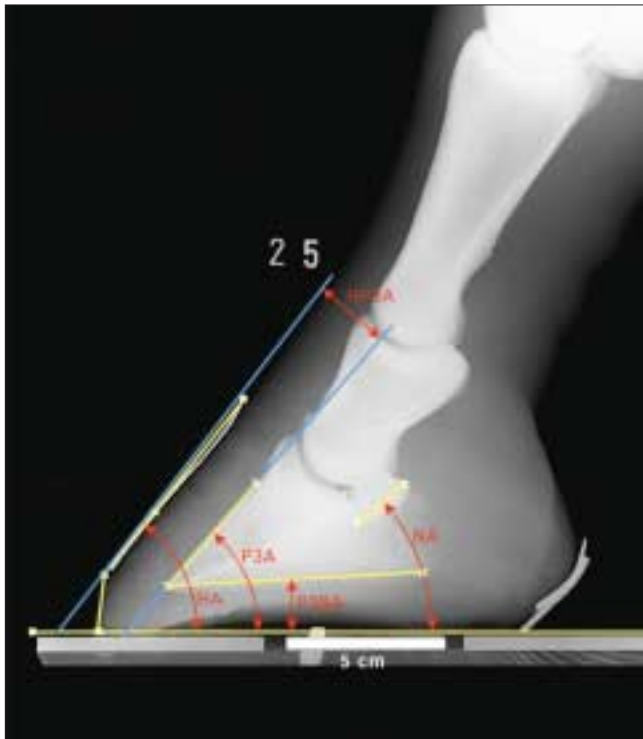

Figure 5. Angle measurements of the laterolateral radiograph. P3A: P3 angle, from the dorsal midline of P3 to the ground plane. NA: Navicular Angle, the angle between the axis of the navicular bone and the ground. HA: Hoof Angle, the angle between the dorsal hoof wall and the ground, as it would be read from a physical “hoof gauge.” HP3A: hoof-P3 angle, the angle of the lines formed by the dorsal hoof wall and the dorsal wall of P3. P3BA: P3 bottom angle, the angle formed between the bottom (palmar surface) of P3 and the ground.

The Measurements

A preliminary evaluation was necessary to reveal possible differences among the measurements obtained with a 75% or a 150% magnification of the digitalized images. To find the magnification with the smallest variation among the individual measurements, 22 parameters in the lateromedial radiographs were measured 10 times by the same operator at both magnifications.

In a second step, repeated measurements of all parameters that are included in the Metron-PX program for the dorsopalmar and the lateromedial radiographs (Figs 3-7) were carried out to investigate the effect of the same operator (A), different operators (B), and the radiographic technique (C). Test A was carried out to establish the variability of repeated measurements of the same digital radiograph by 1 operator (VJ). Test B was performed

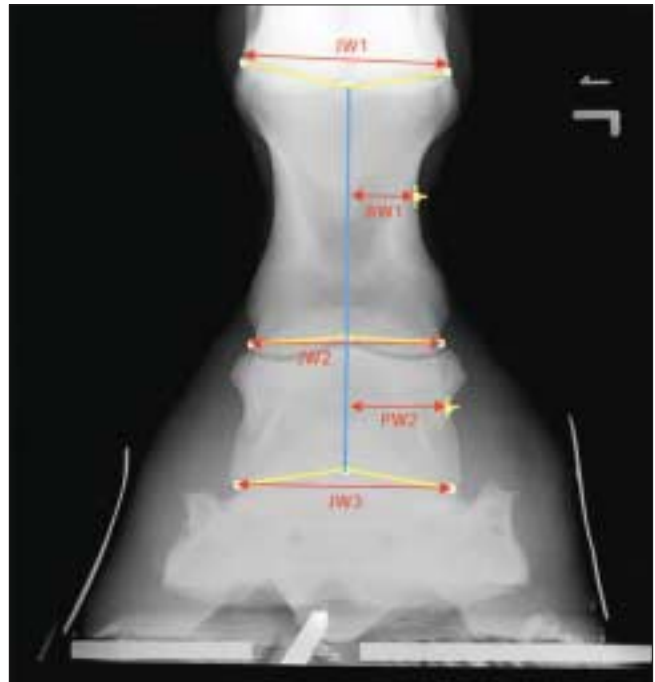

Figure 6. Bone parameters of a dorsopalmar radiograph. JW1: Metacarpal—P1 joint width. JW2: P1-P2 Joint width. JW3: P2-P3 joint width. The width of the joint is the distance between the most medial and lateral aspects of each joint. BW1: P1 Bone Width. BW2: P2 Bone width. The width of the P1 and P2 bones is the value for the distance from the “axis” of the bone (blue line) to the narrowest part of the bone as seen from this view.

to determine the effect caused by different operators not experienced with Metron PX. Fifteen different operators each evaluated 22 parameters of the same digital radiograph. The effect of the radiographic technique was examined by taking 30 lateromedial and dorsopalmar radiographs of an equine foot kept in the same position throughout the procedure (Test C). After each projection, the movable arm was rotated 90° back and forth to necessitate the reaiming of the central beam on the desired position below the coronary band (see Fig 2). The resulting radiographs were evaluated by 1 operator (VJ). When all radiographs were taken, the feet were frozen again.

Two weeks later, sagittal sections were made by cutting the specimens with a band saw. Pictures were taken of the medial and the lateral half using a Minolta Dimage 7 digital camera. On each picture, a ruler of defined length was incorporated. The digitalized picture was imported into the Metron PX software package and the parameters were measured by VJ as described for the radiographs.

The measurements taken from anatomic specimens served as the standard for comparison with the corresponding radiographic measurements. It was impossible to cut a dorsopalmar section, which would allow the anatomic structures to be objectively viewed in the same way as they would be exposed in a radiograph.

All measurements of the digital images of radiographs and sagittal sections were obtained through the application of the guided marks of the Metron-PX program, following the instructions given by the program itself.

STATISTICAL ANALYSES

The data were analyzed using the Stat view 5.0. Further analysis of variance for repeated measurements was used to determine the differences among the 3 tests and the sagittal section. A critical probability of $P = .05$ (5%) was assumed and was based on a 2-sided null hypothesis of no difference. Variability (coefficient of variation) was measured by dividing the mean by the SD. Accuracy and repeatability for the different parameters were considered excellent when the coefficient of variation was smaller than .05.

RESULTS

The preliminary evaluation showed that the coefficient of variation obtained in the images with a 150% magnification presented less variability (.073) than the images obtained with a 75% magnification (2.49). Therefore in this study the 150% magnification was selected to evaluate the Metron-PX software.

Lateromedial View

Mean and coefficient of variation of all parameters of the hoof obtained in each of the 4 tests are shown in Table 1. The majority of the measured parameters showed a coefficient of variation smaller than .05. In 4 (HD, NA, HP3A, P3BA) of 19 parameters of the lateromedial view, coefficient of variation was $>.05$ in 2 or more tests. In general, the SD and the SE was very low. Analysis of variance and Bonferroni adjustment tests revealed various statistically significant differences among the measurements obtained. The differences were most pronounced in the comparison between the anatomic section and the radiographs.

Parameters for the Digital Bones (Bone Parameters)

From the digital bone parameters, the variable that showed the least variation was the radius of the distal interphalangeal articulation (JR3). The parameter founder distance was significantly smaller on the anatomic sec-

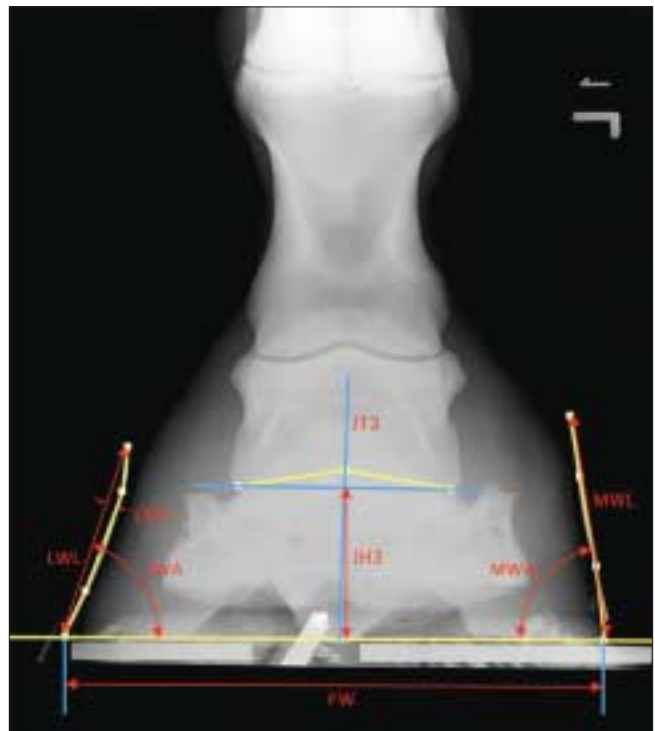

Figure 7. Joint and hoof parameters of a dorsopalmar radiograph. LWL: Lateral wall length, from the hairline to the lateral distal hoof rim. LWA: Angle between the lateral wall and the ground. LWD: Lateral wall deviation, longest perpendicular distance from the LWL to the contour of the lateral hoof wall. MWL: Medial wall length, from the hairline to the medial distal hoof rim. MWA: Angle between the medial wall and the ground. MWD: Medial wall deviation, longest perpendicular distance from the MWL to the contour of the medial hoof wall (not measurable in this radiograph). FW: Foot width, distance between medial and lateral hoof rim. JH3: P2-P3 Joint Height, vertical distance between the ground and the blue line connecting the most medial and most lateral aspect of the P2-P3 joint. JT3: P2-P3 Joint Tilt, Angle between the perpendicular line to the ground and the perpendicular line to horizontal blue line connecting the most medial and most lateral aspect of the P2-P3 joint.

tion (Test D) than on the corresponding radiographs (Tests A-C).

Parameters for the Hoof Capsule (Hoof Parameters)

In 6 of the 13 parameters of the hoof capsule, the anatomic section revealed significantly higher values than corresponding radiographs (P3G, P3T, JH3, HD, NA, P3BA).

Table 1 Summary of means and variation coefficients of Pearson (mean / var. coeff) for the digital bone and the hoof capsule parameters on the lateromedial radiographic projection measured with the MetronPX software.

	Lateromedial Radiographs			Anatomical Section	ANOVA P < 0.05
	TEST A	TEST B	TEST C	TEST D	
Bone parameters (distances in cm)					
JR2	1.65/0.007	1.65/0.006	1.59/0.019	1.50/0.06*	D: B
JR3	1.44/0.006	1.39/0.035	1.42/0.047	1.40/0.035	
LP2	4.91/0.01	4.87/0.004	4.89/0.008	4.88/0.016	A: B
LP3	5.95/0.10*	5.91/0.003	5.93/0.008	5.90/0.013	
NW	1.99/0.02	2.03/0.014	2.00/0.055*	1.94/0.11	
FD	1.17/0.026	1.18/0.025	1.14/0.035	0.79/0.16*	D: A, B, C
Hoof capsule parameters (distances in cm)					
P3G	1.41/0.035	1.39/0.014	1.38/0.021	1.62/0.030	D: A, B, C
P3T	2.05/0.019	2.00/0.01	1.99/0.020	2.24/0.017	D: A, B, C
JH3	4.67/0.006	4.68/0.006	4.62/0.017	5.03/0.023	D: A, B, C
FL	13.43/0.005	13.04/0.007	13.12/0.019	13.08/0.021	B: A, C, D
FLat (%)	57.73/0.012	58.5/0.007	58.91/0.022	59.22/0.016	
HD	0.88/0.056*	0.88/0.045	0.93/0.118*	1.09/0.110	D: A, B, C
HP3	1.62/0.018	1.6/0.012	1.55/0.038	1.59/0.025	
DWL	4.91/0.010	4.87/0.004	4.89/0.008	4.88/0.016	
Hoof capsule parameters (angles in degree)					
P3A	48.36/0.010	48.33/0.004	47.92/0.009	48.42/0.004	C: B, D
NA	39.27/0.056*	38.4/0.025	36.44/0.066*	40.36/0.038	D: B, C
HA	52.58/0.006	52.4/0.004	52.6/0.008	50.92/0.002	
HP3A	-4.21/0.102*	-4.1/0.068*	-3.76/0.74*	-1.09/0.844*	D: A, B
P3BA	5.53/0.112	5.86/0.058*	5.13/0.194*	10.32/0.058*	D: A, B, C

Test A: To determinate the variance effected by the same operator taken repeated measurements on the radiograph.

Test B: To determinate the variance caused by different operators taking the same measurements on the same radiograph.

Test C: To determinate the influence of the radiographic technique.

Test D: Software measurements corresponding to measurements of the anatomic sections (Anatomical Standard)

*Measurements with variation coefficient >0.05

Horizontal Dorsopalmar View

The comparison of the measurements of the dorsopalmar radiographs are shown in Table 2. Four (JW3, LWD, MWD, JT3) of the 14 parameters showed a coefficient of variation >.05 in 2 or more tests. There were less significant differences among tests than in the measurements taken of the lateromedial radiographs.

The greatest variation among tests for the dorsopalmar view was seen in the different measurements of the medial wall of the hoof, especially in the angle of the medial wall; this degree of variability resulted mainly from measurements obtained in Test A, where the mean value was almost 10 degrees higher than in Tests B and C, respectively.

DISCUSSION

Before software for computerized measurements of radiographs was available, such measurements were

made by drawing directly on the film on a light box or on templates laid over the original radiographs. Although this method was not found to be a significant source of variation even among observers,⁹ it is extremely time-consuming and the tracing of the radiographs is an additional source of error.

When radiographs are used for quantitative assessment, a marker of known length has to be placed perpendicular to the central beam and in the same plane as the structures of interest (eg, in the sagittal plane in the lateromedial radiograph).¹³ The magnification factor can be calculated if the focus-object distance is known. In all software applications for hoof measurement, a calibration system requiring a defined marker is included.

The Metron-PX software has a capacity of magnification from 25% to 200%: this has the advantage of allowing measurements to be made at different magnifica-

Table 2 Summary of the means and variation coefficients of Pearson (mean/var. coeff) for the digital bone and hoof capsule parameters measured on the dorsopalmar radiographic view with the MetronPX software

	Dorsopalmar Radiographs			ANOVA <i>P</i> < 0.05
	TEST A	TEST B	TEST C	
Digital bone parameters				
JW1 (cm)	5.82 / 0.013	5.78 / 0.022	5.84 / 0.005	
JW2 (cm)	5.56 / 0.034	5.63 / 0.033	5.58 / 0.005	
JW3 (cm)	5.86 / 0.136*	5.18 / 0.057*	4.56 / 0.054*	A: B, C; B: C
BW1 (cm)	2.24 / 0.084*	2.49 / 0.156	2.41 / 0.012	
BW2 (cm)	2.95 / 0.006	3.01 / 0.023	2.96 / 0.013	
Hoof parameters				
LWL (cm)	6.84 / 0.007	6.85 / 0.023	6.82 / 0.002	
LWA (°)	84.99 / 0.016	84.26 / 0.019	84.22 / 0.015	
LWD (cm)	0.26 / 1.115*	0.17 / 0.941*	0.13 / 1.000*	B: A, C
MWL (cm)	7.13 / 0.016	7.27 / 0.002	7.32 / 0.010	
MWA (°)	83.48 / 0.12*	75.46 / 0.028	73.14 / 0.030	A: B, C
MWD (cm)	2.55 / 0.79*	0.76 / 0.342	0.84 / 2.190*	A: B, C
FW (cm)	14.08 / 0.002	14.08 / 0.018	14.07 / 0.007	
JH3 (cm)	5.78 / 0.039	5.77 / 0.027	5.73 / 0.003	
JT3 (°)	-0.19 / 6.315*	0.58 / 0.996*	-0.05 / 10.2*	

Test A: To determinate the variance effected by the same operator taken repeated measurements on the radiograph.

Test B: To determinate the variance caused by different operators taking the same measurements on the same radiograph.

Test C: To determinate the influence of the radiographic technique.

*Measurements with variation coefficient > 0.05

tions. In the first part of this study, 2 magnification levels were tested for accuracy (75% and 150%). The measurements obtained with a 150% magnification present a lesser variability than the 75% magnification; therefore the 150% magnification was selected for the evaluation of the Metron-PX software in this study. At a higher magnification, it was more difficult to find the desired position of a specific point on the radiograph because of loss of the general view.

The practical handling of the software is relatively easily learned; the user needs approximately 2 hours to get acquainted with the program. A window offering practical advice can help the user at any position within the program. In the current study, the way in which the measurements of the anatomic structures of the equine hoof were taken and the exactness of these measurements are more important than the values measured, as these vary in individual hooves. Certain hoof shapes and bone irregularities may cause greater variability than those specimens used for this study, but minimal variation in measured parameters by the same operator (Test A) indicate sufficient repeatability of most parameters.

Other authors^{9,14} stated that different operators may not agree on the placement of the measuring points owing to incongruity in the radiographic interpretation. For measurements of the founder distance on a single foot, the maximum difference among operators was 4.9

mm.⁹ In our study, the maximum difference in this parameter was 0.9 mm (data not shown).

With few exceptions, different operators (Test B) achieved a good repeatability for most parameters. The parameter P3BA (bottom angle) displayed the biggest dispersion of data (maximum difference 9.12°; data not shown). This can be explained by the diffuse ossification of the posterior contour of the distal palmar of P3, which presents a major difficulty when determining the exact location of distal palmar process of P3 on the digital image of the radiograph.

Nevertheless, the most interesting fact in this study is that the SD of all linear parameters was low. In comparison with results of Tests A and B, the variance among measurements of repeated radiographs (Test C) is small and without clinical significance, which indicates a good quality of the performed radiographic technique.¹³

Concerning the relation of Tests A, B, and C with Test D (anatomic standard), the measurement of the P3 ground angle shows very different values between the digital image of the radiograph and the photo of the medial sagittal cut. This could be explained by the fact that it is impossible to localize the distal palmar processes of P3 in the sagittal cut. The measurement of this angle is carried out by marking the axial region of the palmar surface of the P3, which is always on the inferior contour of the palmar process of the bone.

The measurements of the angle and the deviation of the medial hoof wall on the dorsopalmar images showed a large difference between Test A (single operator) and Tests B and C, respectively. Therefore it can be assumed that the error depends on the operator who was measuring and not on the exactness of the software (especially in the angular measurements).

Veterinarians may use the program for 2 specific reasons: first, to show and illustrate graphically a problem or pathologic process to an owner, farrier, or trainer and to help plan the next shoeing or treatment; second, to establish a common dialogue in the form of standard parameters so that people can begin to study feet from the same points of reference.

Our results suggest that most of the parameters recommended by the manufacturer of the Metron-PX software package can be used with enough accuracy to quantitatively describe the equine hoof, provided high quality and standardized radiographic technique is available.

REFERENCES

1. O'Grady S, Poupard E. Physiological horseshoeing: an overview. *Equine Vet Educ* 2001;AE:426-30.
2. Balch O, White K, Butler D, Metcalf S. Hoof balance and lameness: improper toe length, hoof angle, and mediolateral balance. *The Compendium* 1995;17:1275-1282.
3. Colles CM. Interpreting radiographs 1: The foot. *Equine Vet J* 1983;15:297-303.
4. Tellhelm B, Fritsch R, Reckels FJ. Zur optimalen röntgenologischen darstellung der pferdezehe unter praxisbedingungen. *Tierärztl Prax* 1988;16:395-401.
5. Caudron I, Miesen M, Grulke S. Clinical and radiographic assessment of corrective trimming in lame horses. *J Equine Vet Sci* 1997;17:375-9.
6. Page B. Evaluating the position of the coffin bone relative to the hoof capsule. *J Equine Vet Sci* 2001;21:249.
7. Linford RL, O'Brien TR, Trout DR. Qualitative and morphometric radiographic findings in the distal phalanx and digital soft tissues of sound thoroughbred racehorses. *Am J Vet Res* 1993;54:38-51.
8. Redden RF. Radiographic imaging of the equine foot. *Vet Clin North Am Equine Pract* 2003;19:379-92.
9. Cripps PJ, Eustace RA. Radiological measurements from the feet of normal horses with relevance to laminitis. *Equine Vet J* 1999;31:427-32.
10. Quick CB, Rendano VT. Equine radiology the pastern and foot. *Mod Vet Pract* 1977;58:1022-7.
11. Balch O, Butler D, Collier MA. Balancing the normal foot: hoof preparation, shoe fit and shoe modification in the performance horses. *Equine Vet Educ* 1997;9:143-54.
12. Turner TA. New focus on the foot. *The Horse* 2002;33-46.
13. Kummer M, Lischer C, Vargas J, et al. Evaluation of a standardised technique to take radiographs of the equine hoof. *Schweiz Arch Tierheilk* 2004 (in press).
14. Mason DR, Schulz KS, Samii VF, Fujita Y, Hornof WJ, Herrgesell EJ, et al. Sensitivity of radiographic evaluation of radio-ulnar incongruence in the dog in vitro. *Vet Surg* 2002;31:125-32.