

## General Articles

# Diagnostic accuracy of digital photography and image analysis for the measurement of foot conformation in the horse

J. M. WHITE\*, D. J. MELLOR†, M. DUZ, C. J. LISCHER and L. C. VOUTE

*Weipers Centre Equine for Equine Welfare, Division of Companion Animal Sciences and †Institute of Comparative Medicine, Faculty of Veterinary Medicine, University of Glasgow, Glasgow G61 1QH, UK.*

**Keywords:** horse; diagnostic accuracy; precision; foot conformation; Metron-PX

### Summary

**Reasons for performing study:** Rigorous evaluation of practicable methods for the objective assessment of foot conformation has not been performed.

**Objectives:** To assess the practicability, precision and accuracy of the process of obtaining measurements of horses' feet using photography and image processing software.

**Methods:** *Precision study:* Lateral photographs of horses' feet were obtained twice by 2 veterinary surgeons (image acquisition - IAc). Photographs were analysed by 2 masked veterinary surgeons on 2 occasions (image analysis - IAn). Measurements were compared within and between operators for self and non-self acquired photographs. Agreement indices (AIs) and 95% limits of agreement (LOA) were calculated for the IAn process alone and for the combined IAc + IAn processes. *Accuracy study:* Measurements obtained from lateral photographs were compared with those obtained from lateromedial radiographs. AIs and 95% LOA were calculated for each measurement.

**Results:** *Precision study:* Mean intra- and interoperator AIs for the IAn process alone were  $\geq 0.90$  while those for the combined IAc + IAn processes were  $\geq 0.89$  for all measurements. Similar mean AIs and 95% LOA were calculated regardless of image origin. The 95% LOA for hoof angle, heel height/toe height% and coronary band angle for all comparisons were within target values. *Accuracy study:* Mean AIs were  $\geq 0.89$  for all measurements. The 95% LOA for heel height/toe height% and coronary band angle were within target values.

**Conclusions:** Excellent precision was identified within and between operators regardless of image origin. High levels of accuracy were also identified, especially for heel height/toe height% and coronary band angle, indicating that photography and radiography may be used interchangeably.

**Potential relevance:** Acquisition and analysis of photographic images is an appropriate method for the objective measurement of foot conformation, both in clinical and research settings.

### Abbreviations

AI	Agreement index
DDFT	Deep digital flexor tendon
IAc	Image acquisition
IAn	Image analysis
LOA	Limits of agreement
VS	Veterinary surgeon

### Introduction

Experimental studies have shown that foot conformation influences the forces experienced by the distal limb (Riemersma *et al.* 1996; Wilson *et al.* 1998; Willemen *et al.* 1999; Eliashar *et al.* 2004). Clinical studies have highlighted the importance of foot conformation as a risk factor for musculoskeletal injury (Kane *et al.* 1998; Anderson *et al.* 2004), although this has not been a universal finding (Weller *et al.* 2006a).

Objective methods of foot measurement currently available include the use of hoof protractors, radiographic techniques, photographic and 3D motion analysis techniques. Hoof protractors give little information on overall foot dimensions and their precision (agreement between repeated measures) and accuracy (agreement with an accepted reference standard) are questionable (Moleman *et al.* 2005). Measurements made from radiographs, in digital format with radiopaque markers applied to the foot, have been evaluated for precision and accuracy (Kummer *et al.* 2004; Rocha *et al.* 2004) and are used both in clinical practice and research but require expensive equipment and have radiation safety implications for personnel involved in image acquisition.

A 3D motion analysis system has recently been shown to be useful in the measurement of whole body conformation but requires a minimum of 4 video cameras and custom written software, which limits current usage (Weller *et al.* 2006a). In addition, only a small number of measurements were made pertaining to foot conformation possibly as a consequence of the

\*Author to whom correspondence should be addressed.

[Paper received for publication 10.12.07; Accepted 18.03.08]

relatively large size of anatomical markers required. Weller *et al.* (2006b) compared the 3D system with 2D digital photography, but the height of the camera (level of *tuber olecrani*) is likely to have introduced geometric error to foot measurements made from the 2D photographs.

In contrast to using radiography for making objective measurements of feet, digital photography does not require expensive equipment and poses no radiation hazard. This paper describes investigations into the practicability, precision and accuracy of the entire process of obtaining digital photographs, and the use of a digital image processing software program (Metron-PX)<sup>1</sup>. The study was conducted according to the guidelines of the Standards for Reporting of Diagnostic Accuracy (STARD) initiative (Bossuyt *et al.* 2003).

## Materials and methods

### Study population

**Precision study:** Twenty shod Thoroughbred (TB) horses in training were selected randomly from one racing yard. All horses were in routine farriery care. Horses unwilling to stand still on low (6 cm) wooden blocks<sup>1</sup> without sedation were excluded from the study and a replacement chosen at random.

**Accuracy study:** Fifteen consecutive clinical cases undergoing lateromedial front foot radiography at the Weipers Centre Equine Hospital, for farriery purposes or as part of a lameness investigation, were included in the study, conducted between 1st January 2007 and 1st May 2007. Horses with feathers obscuring the coronary band were excluded from the study. Horses were sedated for radiography and underwent photography during the same sedation period.

Both the precision and accuracy studies were approved by the Ethics and Welfare Committee of the Faculty of Veterinary Medicine, University of Glasgow.

### Image acquisition (IAc)

**Precision study:** Lateral digital photographs were obtained with the horses (unsedated) standing with both front feet elevated on purpose built blocks<sup>1</sup> in a stable with a level concrete floor. The left front foot was photographed against a white background to provide contrast with the foot. The blocks contained embedded scale markers located in 2 planes to improve the accuracy of measurements and a plaque labelled with the identity of the veterinary surgeon (VS) and the animal's number. A digital camera (Fujifilm Finepix Z1, 5.1 megapixels)<sup>2</sup> set at 3x optical zoom (maximum) was used to obtain digital photographs according to the guidelines provided by the manufacturer of Metron-PX ([www.eponatech.com](http://www.eponatech.com)).

The photographic technique included visually aligning the heel bulbs as is done when obtaining lateromedial radiographs (Kummer *et al.* 2004) and supporting the camera at the same level as the foot using a bean bag platform (The Pod)<sup>3</sup>. Two veterinary surgeons (VS1 and VS2), working independently, alternately placed markers on the heel of the foot, obtained a photograph and then carefully removed all trace of the markers. Each VS obtained 2 photographs of each foot in an alternating sequence (e.g. VS1, VS2, VS1, VS2) with the first VS to photograph the foot chosen at random. The markers consisted of 3 mm diameter stainless steel

ball bearings attached with double sided adhesive tape to the palmar aspect of the lateral heel at the level of the coronary band and at the palmar most weightbearing surface, determined using a scalpel blade pushed under the lateral wall in a dorsal direction between the lateral wall and the shoe, whilst the horse was fully weightbearing (Eliashar *et al.* 2004).

**Accuracy study:** Lateral digital photographs were obtained of both fore feet using the same technique as in the precision study by a senior clinical scholar (resident) at the Weipers Centre Equine Hospital.

The reference standard for evaluating a new diagnostic test is the best available method for establishing the presence or absence of disease (Bossuyt *et al.* 2003). In the context of objective measurement of the foot conformation, the reference standard was considered to be lateromedial foot radiography followed by analysis with the Metron-PX software as the precision and accuracy of these techniques have been determined (Kummer *et al.* 2004; Rocha *et al.* 2004).

Lateromedial digital radiographs were obtained of the fore feet with both feet elevated on the blocks with the heel markers attached and following the application of a 7 cm wire marker to the dorsal hoof wall with the proximal extremity at the level of the coronary band. Computed radiographs were obtained with a gantry mounted x-ray unit (CPI Indico100 generator)<sup>4</sup> and digital cassettes (CR MD 4.2)<sup>5</sup>, which were digitised (CR 35X)<sup>5</sup> and exported as JPEG files for image analysis. Radiographs were obtained with a 100 cm film focus distance (FFD) and an 8–10 cm object film distance (OFD) with the x-ray beam centred 2 cm distal to the coronary band at a point mid-way between the dorsal and palmar borders (Kummer *et al.* 2004).

Case details were recorded in customised data entry forms for the accuracy study.

### Image analysis (IAa)

**Precision study:** All images were randomised and then relabelled with a code number using Adobe Photoshop 5.0<sup>6</sup> by the first author. Coded images were imported into Metron-PX version 3.0 and analysed independently by the 2 VSs using the semi-automated (guided) analysis function of the software on 2 occasions. Both VSs received a short tutorial (approximately 30 min) from the first author on the use of the software for photographic images and used the help function of the software when necessary. The following lengths, angles and percentages were recorded from each analysed image: hoof angle; dorsal hoof length; heel angle; heel height; support length; heel height/toe height%; and coronary band angle (Figs 1–3).

**Accuracy study:** Photographic and radiographic images were randomised and coded as for the precision study. Coded photographic images were imported into Metron-PX version 3.0 and analysed as for the precision study. Coded radiographic images were imported into Metron-PX version 3.0 and analysed by VS1 with a combination of semi-automated (guided) and free analysis functions. VS1 received a short tutorial (approximately 30 min) from the first author on the use of the software for radiographic images and used the help function in the software when necessary. The same lengths angles and percentages were recorded from each analysed image as for the precision study.


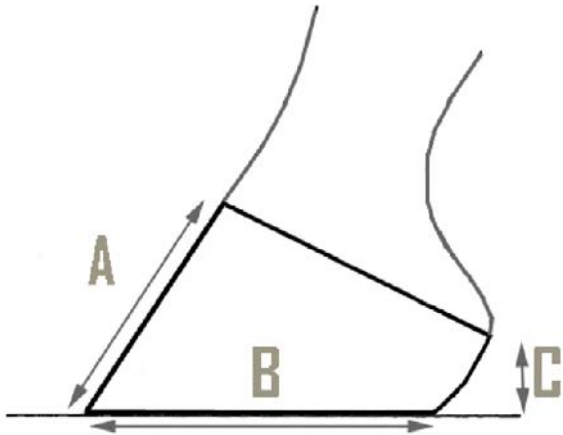


Fig 1: Schematic and screenshot illustrations of the lengths measured using Metron-PX from lateral digital photographs of the foot. A = dorsal hoof length, B = support length, C = heel height.


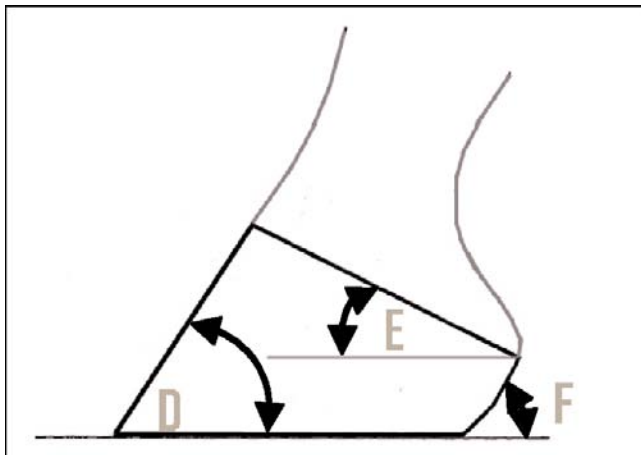


Fig 2: Schematic and screenshot illustrations of the angles measured using Metron-PX from lateral digital photographs of the foot. D = hoof angle, E = coronary band angle, F = heel angle.


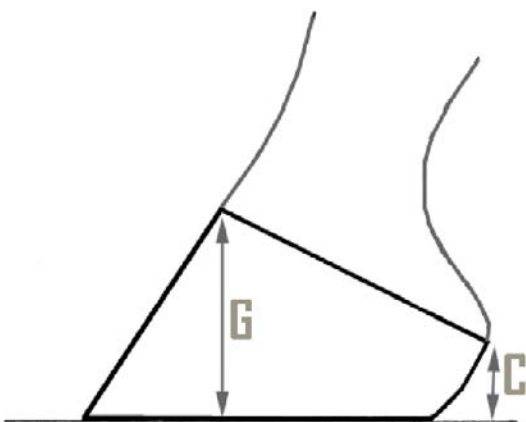


Fig 3: Schematic and screenshot illustrations of the percentage calculated by Metron-PX from lateral digital photographs of the foot. C = heel height, G = toe height, used in the calculation of heel height/toe height% = (C/G) x 100.

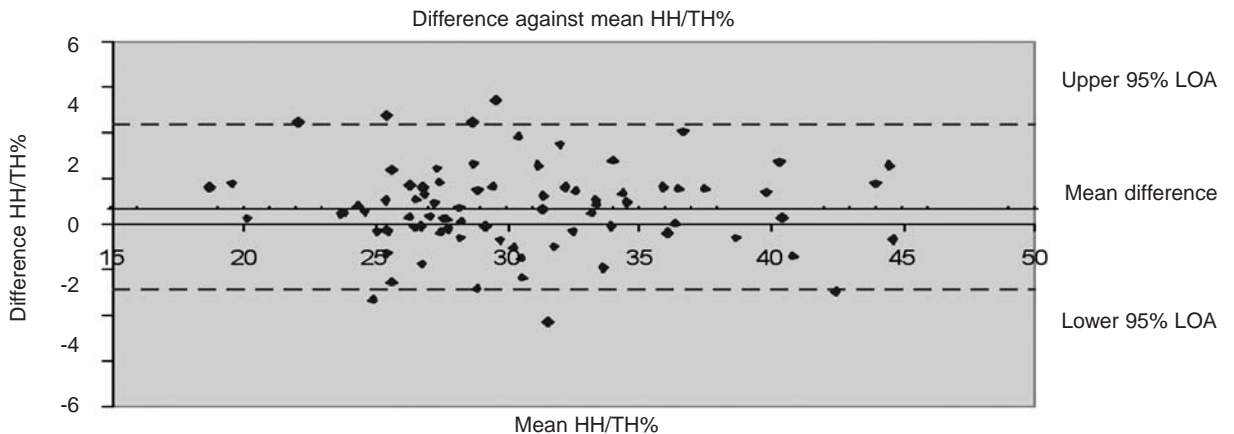


Fig 4: Bland-Altman plot of VS1 intraoperator data for the heel height/toe height% (HH/TH%) measurements. Data points plotted are the differences between repeated measurements against the mean of the repeated measurements. The solid line represents the mean difference between repeated measurements and the dashed lines represent the upper and lower 95% limits of agreement (LOA).

#### Data analysis

**Precision study:** Intra- and interoperator agreement indices (AI) were calculated for the image analysis process alone using the data from the total number of images (80 images), which were analysed on 2 separate occasions and for the combined image acquisition and image analysis processes for both self and non-self acquired images. The following AI equation was used (Filippi *et al.* 1995; van der Vlugt-Meijer *et al.* 2006):

$$AI = 1 - [|X_a - X_b| / \{(X_a + X_b) / 2\}]$$

where an AI of 1 indicates perfect agreement and mean AIs  $\geq 0.90$  represent excellent agreement (van der Vlugt-Meijer *et al.* 2006). To calculate interoperator agreement indices,  $X_a$  was the measurement obtained by VS1 and  $X_b$  the measurement obtained by VS2. Both first and second measurements were used for the calculations of interoperator AIs. For the intraoperator AIs,  $X_a$  was the first measurement and  $X_b$  the second measurement obtained by the same VS. The mean  $\pm$  s.d. was calculated for the inter- and intraoperator AIs. In addition, 95% limits of agreement (LOA) were calculated using the equation: 95% LOA = mean difference  $\pm$  1.96 s.d. (Bland and Altman 1986, 2003).

Bland-Altman plots of the difference vs. mean of repeated measures (Fig 4) and histograms to assess the distribution of differences were constructed for all analyses to check the assumptions of the data and the suitability of the 95% LOA method (Bland and Altman 1986, 2003).

**Accuracy study:** Agreement indices were calculated between the photographic and radiographic measurements using the same AI equation as in the precision study, but substituting  $X_a$  with the radiographic measurement and  $X_b$  with the photographic measurement. The mean  $\pm$  s.d. for the AIs and the 95% LOA were calculated as shown above.

As no data are currently available that quantify clinically significant changes in foot conformation the 95% LOA were compared to target values that represented the smallest changes that a veterinary surgeon or farrier is likely to make to foot conformation during trimming and shoeing. These were estimated to be 5 mm for length measurements, 5° for angle measurements and 10% for percentage calculations.

#### Results

##### Precision study

Horses were age 2–12 years (median 5 years) and included 14 geldings, 3 colts and 3 fillies/mares. One horse was excluded from the precision study because of unwillingness to stand for the repeated image acquisition process necessary for the study and another horse recruited at random.

**Image analysis process alone (IAN):** The image analysis process for each image took approximately one minute to complete. Mean intraoperator AIs for both VS1 and VS2 were  $\geq 0.90$  with s.d.  $< 0.10$  for all 7 measurements recorded (Table 1). Mean interoperator AIs were  $\geq 0.90$  with s.d.  $< 0.10$  for all 7 measurements recorded (Table 2). The 95% limits of agreement for hoof angle, heel height/toe height% and coronary band angle were less than the target values for all intra- and interoperator comparisons (Tables 1, 2).

**Combined image acquisition + image analysis processes (IAC + IAN):** The image acquisition process for each image took approximately 2 min to complete. Mean intraoperator AIs for both VS1 and VS2 for both self and non-self acquired digital photographs were  $\geq 0.89$  with s.d.  $\leq 0.10$  for all 7 measurements recorded

TABLE 1: Intraoperator agreement indices and 95% limits of agreement of measurements for the image analysis process alone for VS1 and VS2

Hoof measurement	VS	Agreement index (mean $\pm$ s.d.)	95% limits of agreement
Hoof angle	1	0.98 $\pm$ 0.01	-2.47–1.75°
	2	0.98 $\pm$ 0.02	-1.11–2.95°
Dorsal hoof length	1	0.97 $\pm$ 0.03	-0.80–0.41 cm
	2	0.97 $\pm$ 0.04	-0.85–0.82 cm
Heel angle	1	0.96 $\pm$ 0.03	-3.17–3.17°
	2	0.93 $\pm$ 0.06	-6.48–5.89°
Heel height	1	0.95 $\pm$ 0.04	-0.27–0.27 cm
	2	0.91 $\pm$ 0.08	-0.50–0.58 cm
Support length	1	0.99 $\pm$ 0.02	-0.56–0.47 cm
	2	0.98 $\pm$ 0.04	-0.77–0.88 cm
Heel/toe height%	1	0.95 $\pm$ 0.05	-2.92–4.33%
	2	0.92 $\pm$ 0.08	-6.90–7.20%
Coronary band angle	1	0.95 $\pm$ 0.03	-3.37–1.27°
	2	0.95 $\pm$ 0.04	-3.20–3.30°

**TABLE 2: Interoperator agreement indices and 95% limits of agreement of measurements for the image analysis process alone between VS1 and VS2**

Hoof measurement	Agreement index (mean ± s.d.)	95% limits of agreement
Hoof angle	0.98 ± 0.01	-2.32–1.37°
Dorsal hoof length	0.97 ± 0.03	-0.43–0.73 cm
Heel angle	0.91 ± 0.06	-6.90–1.94°
Heel height	0.90 ± 0.08	-0.55–0.18 cm
Support length	0.99 ± 0.02	-0.54–0.42 cm
Heel/toe height (%)	0.90 ± 0.08	-8.10–2.04%
Coronary band angle	0.94 ± 0.04	-1.45–3.90°

**TABLE 3: Intraoperator agreement indices and 95% limits of agreement of measurements for the combined image acquisition and analysis processes for VS1 and VS2 for self (S) and non-self (NS) acquired images**

Hoof measurement	(S/NS) VS	Agreement index (mean ± s.d.)	95% limits of agreement
Hoof angle	S1	0.99 ± 0.01	-1.61–1.90°
	S2	0.99 ± 0.01	-1.78–1.70°
	NS1	0.99 ± 0.01	-1.27–1.37°
	NS2	0.99 ± 0.01	-1.66–2.13°
Dorsal hoof length	S1	0.97 ± 0.02	-0.60–0.60 cm
	S2	0.98 ± 0.01	-0.85–0.82 cm
	NS1	0.97 ± 0.02	-0.77–0.65 cm
	NS2	0.97 ± 0.04	-0.68–0.94 cm
Heel angle	S1	0.91 ± 0.08	-7.17–7.47°
	S2	0.91 ± 0.05	-7.58–5.39°
	NS1	0.92 ± 0.05	-6.52–5.45°
	NS2	0.89 ± 0.07	-7.01–9.70°
Heel height	S1	0.90 ± 0.07	-0.54–0.43 cm
	S2	0.92 ± 0.05	-0.54–0.36 cm
	NS1	0.90 ± 0.07	-0.60–0.51 cm
	NS2	0.91 ± 0.10	-0.47–0.64 cm
Support length	S1	0.96 ± 0.03	-1.08–1.17 cm
	S2	0.97 ± 0.02	-0.88–0.77 cm
	NS1	0.97 ± 0.02	-0.81–0.69 cm
	NS2	0.96 ± 0.05	-1.26–1.71 cm
Heel/toe height (%)	S1	0.90 ± 0.06	-7.55–5.74%
	S2	0.92 ± 0.06	-7.47–5.02%
	NS1	0.92 ± 0.07	-7.36–6.57%
	NS2	0.93 ± 0.07	-5.27–6.49%
Coronary band angle	S1	0.94 ± 0.04	-3.11–4.18°
	S2	0.96 ± 0.04	-2.28–3.26°
	NS1	0.95 ± 0.05	-4.03–3.99°
	NS2	0.95 ± 0.03	-2.97–2.89°

**TABLE 4: Interoperator agreement indices and 95% limits of agreement of measurements for the combined image acquisition and image analysis processes between VS1 and VS2 for self (S) and non-self (NS) acquired images**

Hoof measurement	Self/non-self acquisition	Agreement index (mean ± s.d.)	95% limits of agreement
Hoof angle	S	0.99 ± 0.01	-1.95–0.84°
	NS	0.99 ± 0.01	-2.00–1.23°
Dorsal hoof length	S	0.98 ± 0.02	-0.21–0.56 cm
	NS	0.97 ± 0.02	-0.48–0.73 cm
Heel angle	S	0.90 ± 0.06	-8.09–2.84°
	NS	0.92 ± 0.07	-7.08–2.43°
Heel height	S	0.91 ± 0.07	-0.51–0.13 cm
	NS	0.90 ± 0.07	-0.54–0.17 cm
Support length	S	0.98 ± 0.02	-0.73–0.55 cm
	NS	0.97 ± 0.02	-0.83–0.76 cm
Heel/toe height (%)	S	0.90 ± 0.07	-7.39–1.34%
	NS	0.89 ± 0.07	-8.14–2.14%
Coronary band angle	S	0.93 ± 0.04	-0.33–3.74°
	NS	0.93 ± 0.04	-0.92–4.16°

(Table 3). Mean interoperator AIs for the combined process were ≥0.89 with s.d. <0.10 for all 7 measurements recorded (Table 4). The 95% limits of agreement for hoof angle, heel height/toe height% and coronary band angle were less than the target values for all intra- and interoperator comparisons (Tables 3, 4).

*Accuracy study*

Horses were age 1–18 years (median 11 years) and included 5 geldings and 10 fillies/mares. Mean AIs between photographic and radiographic measurements were ≥0.89 with s.d. <0.10 for all 7 measurements recorded (Table 5). The 95% limits of agreement for heel height/toe height% and coronary band angle were less than the target values for all intra- and interoperator comparisons (Table 5).

**Discussion**

High levels of intra- and interoperator agreement were identified for the image analysis process alone and for the combined image acquisition and image analysis processes for all the measurements recorded. Excellent mean AIs were identified for all measurements and the upper and lower 95% LOAs were less than the predetermined target values for hoof angle, heel height/toe height% and coronary band angle for all the intraoperator analyses of both VSs as well as for interoperator analysis between VSs. The 95% LOA were also close to or less than the target values for all other measurements for the analyses. These results suggest that the image analysis process alone and the combined processes necessary to obtain measurements of foot conformation with the software were not associated with unacceptable variation either within or between operators of the software.

Similar mean AIs and 95% LOA were obtained for the combined processes regardless of whether or not the individual who acquired the lateral digital photographs of the foot also analysed them. The implication of this finding is that images acquired by one VS can be analysed by a second VS with results comparable to image analysis performed by the first VS. Therefore, the process described here has potential applications in telemedicine by facilitating the remote analysis of images to provide an expert opinion on foot conformation, and may also be particularly useful in a prospective multicentre longitudinal study further investigating the relationship between foot conformation and musculoskeletal injury where large sample numbers are required to improve the validity of results.

For the image acquisition process in this study, the camera lens was aligned visually by each operator to be perpendicular to the bulbs of the heel. The method was chosen because it is most

**TABLE 5: Agreement indices and 95% limits of agreement between photographic measurements (index test) and radiographic measurements (reference standard)**

Hoof measurement	Agreement index (mean ± s.d.)	95% limits of agreement
Hoof angle	0.95 ± 0.04	-6.31–1.48°
Dorsal hoof length	0.95 ± 0.05	-1.57–1.32 cm
Heel angle	0.89 ± 0.09	-6.83–11.28°
Heel height	0.89 ± 0.08	-0.79–0.42 cm
Support length	0.95 ± 0.06	-1.40–2.13 cm
Heel/toe height (%)	0.92 ± 0.04	-6.76–5.29%
Coronary band angle	0.94 ± 0.06	-4.52–2.10°

likely to be used in a clinical setting. Any variation in measurements arising because of a failure to achieve perfect alignment was not specifically determined but contributed to the estimates of variation involved in the entire image acquisition process.

The study highlights the suitability of the 95% LOA method for agreement studies as despite excellent mean AIs for some parameters, e.g. intraoperator dorsal hoof length and support length measurements (0.96 to 0.98), the calculated 95% LOA were greater than the target values for length measurements (5 mm). However, for these 2 parameters in particular, the magnitude of changes that occur at the toe region during routine trimming and shoeing (Kummer *et al.* 2006) make it probable that greater target lengths would be acceptable.

The levels of agreement and acceptable limits of agreement between heel height/toe height% and the coronary band angle measurements suggest that the radiographic and photographic methods may be used interchangeably for the measurement of these 2 parameters, which are clinically important given their strong correlations with the tension in the DDFT and the force applied to the navicular bone (Eliashar *et al.* 2004). It is probable that the methods may also be used interchangeably for hoof angle and heel height given that their 95% LOA were close to the target values.

Interestingly, intraoperator agreement for the image analysis process did not appear to be directly related to the amount of post-graduate experience of the VS, as VS1 (resident level) attained equivalent or slightly higher AIs for the IAn process alone than VS2 (lecturer). The study also identified similar intraoperator mean agreement indices for the combined image acquisition and image analysis processes. Although the study was confined to just 2 operators the results suggest that highly repeatable results can be achieved by equine practitioners with varying levels of experience.

The study demonstrated that the steps required to make measurements from lateral digital photographs of the fore feet of horses were easily and rapidly accomplished in a clinical setting. Only, one horse was excluded from the precision study due to lack of compliance with the image acquisition process. All other horses, including the unsedated Thoroughbred racehorses, tolerated marker placement and photography standing on wooden blocks on multiple occasions.

There are other software programs capable of making measurements from digital photographs, but direct comparison between these and the Metron-PX system was not the aim of this study. However, the system used in this study has a number of strengths (user friendly interface, semi-automated analysis, help function, purpose-designed blocks, online support, archiving and data export functions) that contribute to ease and speed of use and could make the system attractive to practitioners.

In conclusion, the findings of this study indicate that the entire process necessary for making measurements of foot conformation in the horse, using Metron-PX software, is both practicable and produces measurements with excellent precision and accuracy, especially for measurement of hoof angle, heel height/toe height% and coronary band angle. It is probable that the limits of agreement for the other measurements recorded also reflect acceptable precision and accuracy but further work is required to define clinically significant differences in these measurements. As such the software has applications in both clinical practice and as a research tool.

## Manufacturers' addresses

<sup>1</sup>Epona Tech, Creston, California, USA.

<sup>2</sup>Fuji Photo Film, Tokyo, Japan.

<sup>3</sup>The Pod Industries, Toronto, Ontario, Canada.

<sup>4</sup>Communication & Power Industries, Georgetown, Ontario, Canada.

<sup>5</sup>Agfa-Gevaert, Brentford, Middlesex, UK.

<sup>6</sup>Adobe Systems Europe, Uxbridge, Middlesex, UK.

## References

- Anderson, T.M., McIlwraith, C.W. and Douay, P. (2004) The role of conformation in musculoskeletal problems in the racing Thoroughbred. *Equine vet. J.* **36**, 571-575.
- Bland, J.M. and Altman, D.G. (1986) Statistical methods for assessing agreement between two methods of clinical measurement. *Lancet* **1**, 307-310.
- Bland, J.M. and Altman, D.G. (2003) Applying the right statistics: analyses of measurement studies. *Ultrasound Obstet. Gynecol.* **22**, 85-93.
- Bossuyt, P.M., Reitsma, J.B., Bruns, D.E., Gatsonis, C.A., Glasziou, P.P., Irwig, L.M., Moher, D., Rennie, D., de Vet, H.C. and Lijmer, J.G. (2003) The STARD statement for reporting studies of diagnostic accuracy: explanation and elaboration. The Standards for Reporting of Diagnostic Accuracy Group. *Croat. Med. J.* **44**, 639-650.
- Eliashar, E., McGuigan, M.P. and Wilson, A.M. (2004) Relationship of foot conformation and force applied to the navicular bone of sound horses at the trot. *Equine vet. J.* **36**, 431-435.
- Filippi, M., Horsfield, M.A., Bressi, S., Martinelli, V., Baratti, C., Reganati, P., Campi, A., Miller, D.H. and Comi, G. (1995) Intra- and inter-observer agreement of brain MRI lesion volume measurements in multiple sclerosis. A comparison of techniques. *Brain* **118**, 1593-1600.
- Kane, A.J., Stover, S.M., Gardner, I.A., Bock, K.B., Case, J.T., Johnson, B.J., Anderson, M.L., Barr, B.C., Daft, B.M., Kinde, H., Larochelle, D., Moore, J., Mysore, J., Stoltz, J., Woods, L., Read, D.H. and Ardans, A.A. (1998) Hoof size, shape, and balance as possible risk factors for catastrophic musculoskeletal injury of Thoroughbred racehorses. *Am. J. vet. Res.* **59**, 1545-1552.
- Kummer, M., Geyer, H., Imboden, I., Auer, J. and Lischer, C. (2006) The effect of hoof trimming on radiographic measurements of the front feet of normal Warmblood horses. *Vet. J.* **172**, 58-66.
- Kummer, M., Lischer, C., Ohlerth, S., Vargas, J. and Auer, J. (2004) Evaluation of a standardised radiographic technique of the equine hoof. *Schweiz Arch. Tierheilkd.* **146**, 507-514.
- Moleman, M., van Heel, M.C.V., van den Belt, A.J.M. and Back, W. (2005) Accuracy of hoof angle measurement devices in comparison with digitally analysed radiographs. *Equine vet. Educ.* **17**, 319-322.
- Riemersma, D.J., van den Bogert, A.J., Jansen, M.O. and Schamhardt, H.C. (1996) Influence of shoeing on ground reaction forces and tendon strains in the forelimbs of ponies. *Equine vet. J.* **28**, 126-132.
- Rocha, J.V., Lischer, C.J., Kummer, M., Hassig, M. and Auer, J. (2004) Evaluating the measuring software package Metron-PX for morphometric description of equine hoof radiographs. *J. equine vet. Sci.* **24**, 347-354.
- van der Vlugt-Meijer, R.H., Meij, B.P. and Voorhout, G. (2006) Intraobserver and interobserver agreement, reproducibility, and accuracy of computed tomographic measurements of pituitary gland dimensions in healthy dogs. *Am. J. vet. Res.* **67**, 1750-1755.
- Weller, R., Pfau, T., Verheyen, K., May, S.A. and Wilson, A.M. (2006a) The effect of conformation on orthopaedic health and performance in a cohort of National Hunt racehorses: preliminary results. *Equine vet. J.* **38**, 622-627.
- Weller, R., Pfau, T., Babbage, D., Brittin, E., May, S.A. and Wilson, A.M. (2006b) Reliability of conformational measurements in the horse using a three-dimensional motion analysis system. *Equine vet. J.* **38**, 610-615.
- Willems, M.A., Savelberg, H.H. and Barneveld, A. (1999) The effect of orthopaedic shoeing on the force exerted by the deep digital flexor tendon on the navicular bone in horses. *Equine vet. J.* **31**, 25-30.
- Wilson, A.M., Seelig, T.J., Shield, R.A. and Silverman, B.W. (1998) The effect of foot imbalance on point of force application in the horse. *Equine vet. J.* **30**, 540-545.

**Author contributions** The initiation, conception and planning of this study were by J.M.W., L.C.V., D.J.M. and C.J.L. Its execution by J.M.W., L.C.V. and M.D., with statistics by J.M.W., L.C.V. and D.J.M. The paper was written by J.M.W., L.C.V., D.J.M. and C.J.L.